

New method of temporary rehabilitation after traumatic tooth loss in a juvenile patient: a case report

CASE REPORT

Peter Göllner¹, Britta A. Jung²,
Heinrich Wehrbein², Thomas
Liechti¹

¹Private Practice, Berne, Switzerland;

²Department of Orthodontics, University
Hospital Mainz, Mainz, Germany

Correspondence to: Dr Peter Göllner,
Kieferorthopäde SSO, Spitalgasse 16, 3011
Berne, Switzerland
Tel.: +4 131 311 3240
Fax: +4 131 312 2353
e-mail: goellner@bluewin.ch

Accepted 3 July, 2008

Abstract – We report a 12-year-old female patient who had experienced traumatic loss of one of her permanent central incisors. In the course of interdisciplinary treatment, the gap in the front teeth was filled with a prosthetic plastic tooth fastened to an orthodontic palatal implant by means of a wire extension (stainless steel 1.2 mm; laser-welded). A palatal implant is a temporary orthodontic anchorage device which, in contrast to a conventional single tooth implant, is not inserted in the toothless alveolar bone but in the palatal region to permit unhindered maxillary growth. The advantages of this treatment compared with traditional treatment options are that it permits secure fixation, adjustment to vertical growth and good hygiene. Besides, it is an economical treatment modality, can be used as anchorage in conjunction with orthodontic treatment and provides good comfort, esthetics and phonetics.

The primary goal of treating tooth gaps as a result of trauma in growing patients was to provide provisional or semi-definitive treatment and create optimal conditions for definitive treatment later on. A further important aspect is to gain time for planning definitive interdisciplinary dental care. Traditional treatment options (1) used thus far involve the use of removable dentures in the form of an orthodontic retainer which can easily adjusted in the mixed dentition.

We report a new procedure for temporary oral rehabilitation using an orthodontic palatal implant in a juvenile patient who had experienced dental trauma.

Case report

A 12-year-old patient (Fig. 1a) was referred to the orthodontist's office for a routine check up. Clinical (Fig. 1b) and radiological evaluation (Fig. 2) revealed loss of the right central incisor as a result of trauma. The parents had been unable to find the tooth despite an extensive search. The patient underwent initial care at the practice of the family dentist, whose treatment consisted of an interim prosthesis with a plastic tooth in region 11 (Fig. 3). The patient required further orthodontic treatment for distal occlusion. After orthodontic treatment and completion of growth, the parents wanted the child to receive a conventional single tooth implant in region 11 of the pars alveolaris.

The interdisciplinary treatment concept provides the following procedures:

1 surgical insertion of a palatal implant (3.3 mm in diameter and 4.2 mm in length, Orthosystem, Strau-

- mann, Switzerland; Fig. 4a): This is a temporary orthodontic anchoring implant which is inserted into the palatal area (Fig. 4b) to obtain maximum anchorage by osseointegration. The insertion technique has been previously described in several articles (2–4);
- 2 temporary prosthetic replacement of tooth 11 (Fig. 5a–c) after a healing period of 12 weeks and conventional molding;
- 3 subsequent orthodontic correction of malocclusion and implant insertion in region 11 when alveolar bone growth has been completed.

Discussion

Depending on the patient's age, the main purpose of treating anterior dental trauma was to gain time for the definitive interdisciplinary treatment. The presence of an adequate number of teeth to execute several functions such as chewing and modulation of speech is very important in childhood and adolescence. If, as in this case, loss of a permanent tooth results in a gap of longer duration, the integrated denture for primary care must maintain the gap, prevent tilting of the adjacent teeth, prevent mesial migration of the lateral teeth, and provide sagittal and vertical support. Aspects such as hygiene and dental esthetics are also important.

The method presented in this report for the treatment of a gap between the front teeth after dental trauma in growing patients is based on skeletal anchorage and may serve a useful adjunct to conventional options such as space maintainer or an adhesive bridge (5). It fulfills the above-mentioned functional criteria and its anchorage in

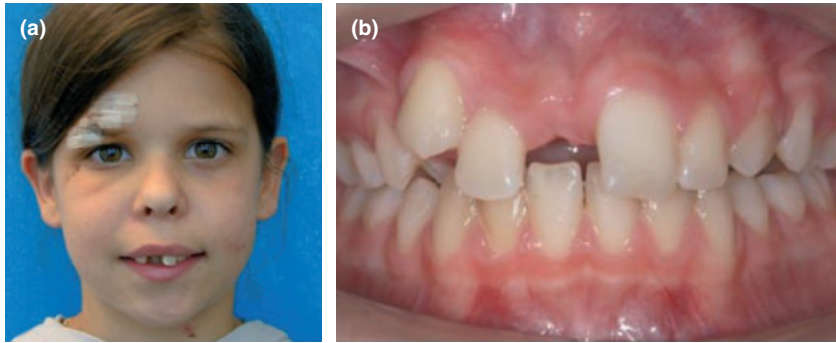


Fig. 1. En-face photograph (a) and intraoral frontal view (b) of the patient after the traumatic loss of tooth 11.

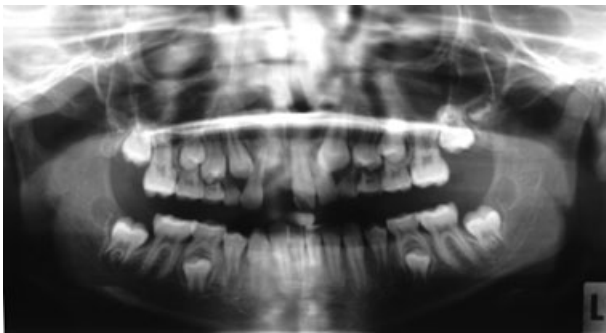

Fig. 2. The orthopantomogram shows the loss of tooth 11.

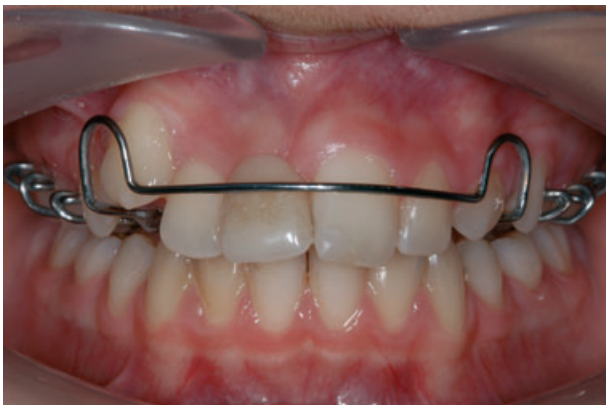

Fig. 3. Traditional care of space is accomplished by means of a modified orthodontic retaining plate and a plastic prosthetic tooth in region 11.

bone ensures stability even during mixed dentition. The risk of implant fracture is to the lever effect of the wire extension (stainless steel 1.2 mm; laser-welded; Fig. 5b), is minimized by the elasticity of the palatal vault (6). Moreover, this denture can be fitted to the vertical growth of the alveolar process at any time by grinding the plastic base. Owing to its small surface and accessibility, it is easy for patients to clean. Further advantages are its wearing comfort, esthetics (Fig. 5c) and phonetics. Additionally, the denture presented here can be used for maximum orthodontic anchorage to correct malocclusion.

Compared with this approach, the disadvantages of traditional treatment options for anterior tooth loss such as the prosthetic removable denture (space maintainer) or the adhesive bridge are worthy of note. The space-maintaining prosthesis usually is an orthodontic retention plate extended around the lost tooth. Its advantage of being easy to adjust in cases of incomplete permanent dentition must be weighed against its significant disadvantage of restricting oral hygiene to such an extent that it may result in a shift of the microbiological spectrum and a severe alteration of the mucous membrane in the mouth. In addition, the removable denture's esthetic outcome is moderate compared with that of a securely fastened denture.

The construction of an adhesive bridge (5) results in loss of the dental hard substance of caries-free neighboring teeth, although this is clearly less than that required for the preparation of conventional bridges. The procedure is very demanding with regard to diagnosis, planning and execution, and may be contraindicated in patients with a deep overbite with impingement

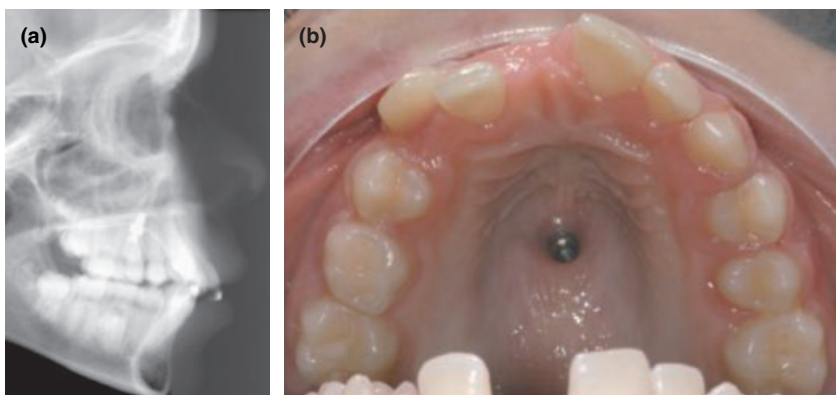


Fig. 4. (a) The cephalometric radiograph shows the condition after surgical insertion of an orthodontic anchoring implant (palatal implant; diameter: 3.3 mm; length: 4.2 mm, Orthosystem, Straumann, Switzerland). (b) Intraoral photograph of the upper jaw after surgical insertion of the palatal implant during the 12-week healing time.

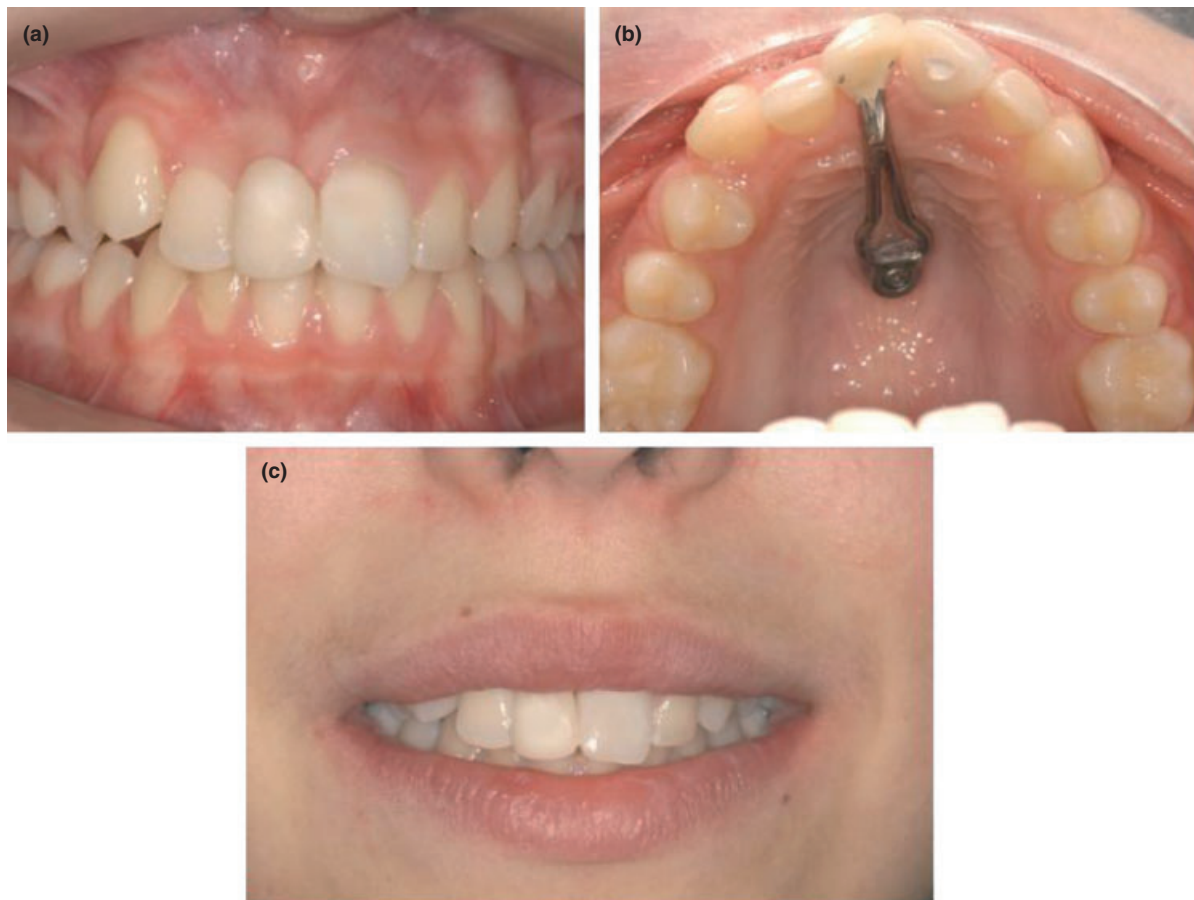

Fig. 5. Photographic findings intraoral (a, b) and extraoral (c) with the new type integrated temporary prosthetic substitution by means of a palatal implant.

on the bridge parts. Furthermore, adhesive bridges are contraindicated in teeth with a short clinical crown, which signifies a smaller adhesive surface, as well as in teeth with marked abrasions and a small enamel surface. Especially when, a growing patient requires orthodontic treatment later because of misalignment of teeth, the adhesive bridge fails to serve its purpose as a provisional measure. In such cases – as in our patient – extensive orthodontic tooth movements are rendered difficult or cannot be performed in the desired manner. Hence, this alternative should be considered when orthodontic tooth movements have been completed.

Further alternatives for primary and/or secondary treatment beyond those discussed here are autotransplantation of teeth (7, 8) or orthodontic space closure (9, 10). Treatment of a space between the front teeth by the use of a conventional single tooth implant is contraindicated in growing patients because of the extensive growth during this time (11). This leads to inhibition of the growth of neighboring bone tissue and also infraocclusion of the single tooth implant in subsequent formative years (11–13).

Conclusion

The availability of skeletal orthodontic anchorage has significantly extended the spectrum of orthodontic as

well as dental treatment. This type of anchorage permits adequate up-to-date treatment even in complex treatment cases such as a front tooth gap after traumatic loss of a permanent tooth. Close interdisciplinary cooperation and extensive knowledge of implantology and orthodontics are important prerequisites for successful application of skeletal anchorage.

References

1. Marinello CP, Schärer P. Einzelzahnersatz beim jugendlichen Patienten. *Schweiz Monatsschr Zahnmed* 1990;100:596–611.
2. Wehrbein H, Merz BR, Diedrich P, Glatzmaier J. The use of palatal implants for orthodontic anchorage. Design and clinical application of the orthosystem. *Clin Oral Implants Res* 1996;7:410–6.
3. Wehrbein H, Glatzmaier J, Mundwiler U, Diedrich P. The Orthosystem – a new implant system for orthodontic anchorage in the palate. *J Orofac Orthop* 1996;57:142–53.
4. Wehrbein H, Feifel H, Diedrich P. Palatal implant anchorage reinforcement of posterior teeth: a prospective study. *Am J Orthod Dentofacial Orthop* 1999;116:678–86.
5. Marinello CP, Soom U, Schärer P. Die Präparation in der Adhäsivprothetik. *Schweiz Monatsschr Zahnmed* 1988;98:138–54.
6. Gedrange T, Bourauel C, Köbel C, Harzer W. Three-dimensional analysis of endosseous palatal implants and bones after vertical, horizontal, and diagonal force application. *Eur J Orthod* 2003;25:109–15.

7. Paulsen HU, Andreasen JO. Eruption of premolars subsequent to autotransplantation. A longitudinal radiographic study. *Eur J Orthod* 1998;20:45–55.
8. Czochrowska EM, Stenvik A, Album B, Zachrisson BU. Autotransplantation of premolars to replace maxillary incisors: a comparison with natural incisors. *Am J Orthod Dentofacial Orthop* 2000;118:592–600.
9. Czochrowska EM, Skaare AB, Stenvik A, Zachrisson BU. Outcome of orthodontic space closure with a missing maxillary central incisor. *Am J Orthod Dentofacial Orthop* 2003;123:597–603.
10. Kugel B, Zeh D, Müssig E. Incisor trauma and the planning of orthodontic treatment. *J Orofac Orthop* 2006;67:48–57.
11. Thilander B, Ödman J, Lekholm U. Orthodontic aspects of the use of oral implants in adolescents: a 10-year follow-up study. *Eur J Orthod* 2001;23:715–31.
12. Wehrbein H. Orthodontische Implantatverankerung. *Kieferorthop* 2004;18:117–124.
13. Bernard JP, Schatz JP, Christou P, Belser U, Kiliaridis S. Long-term vertical changes of the anterior maxillary teeth adjacent to single implants in young and mature adults. A retrospective study. *J Clin Periodontol* 2004;31:1024–8.